


---

# SEATTLE STUDY CLUB

*Cultivating Excellence in Comprehensive Dentistry*

---



# Treatment planning clinical case report

Patient Gerhard Reheusser

Dentist: Dr.med.dent. Armin Enssle  
Dental technician : ZTM S.Schunke



ZAHNGESUNDHEIT  
IN DEN  
SEBALDER HÖFEN

Dr. med. dent. Armin Enssle  
Dc. med. dent. Bettina Enssle



# Treatment Planning

Case study – Patient: Reheusser, Gerhard,  
date of birth: 04.22.1960

- Chief complaint: “Inability to chew well and desires an aesthetic improvement in the appearance of his smile”
- He is working most of his time in the United States and his wish is a white dentition.
- Active person, triathlete, stress, like natural food, workoholic, no CMD problems , very good physical and psychical situation



## Initial Situation

### Initial clinical examination

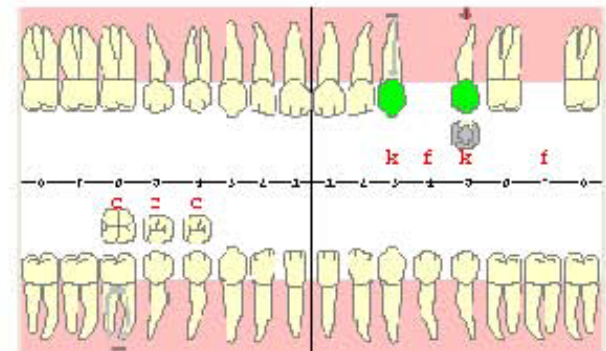
#### Karteikarte

Seite: 1

Datum: 11.03.10

Bereich: markiert

Patient: **Gerhard Reheusser, 22.04.1960**  
 Kasse: PRIVAT GOTHAER  
 Status: P  
 Patienten Nr.: 1141



Datum	Leistungen	Art	Beh	Abg.
11.03.2010	KORBEF (Befundkorrektur)	KC	AE	

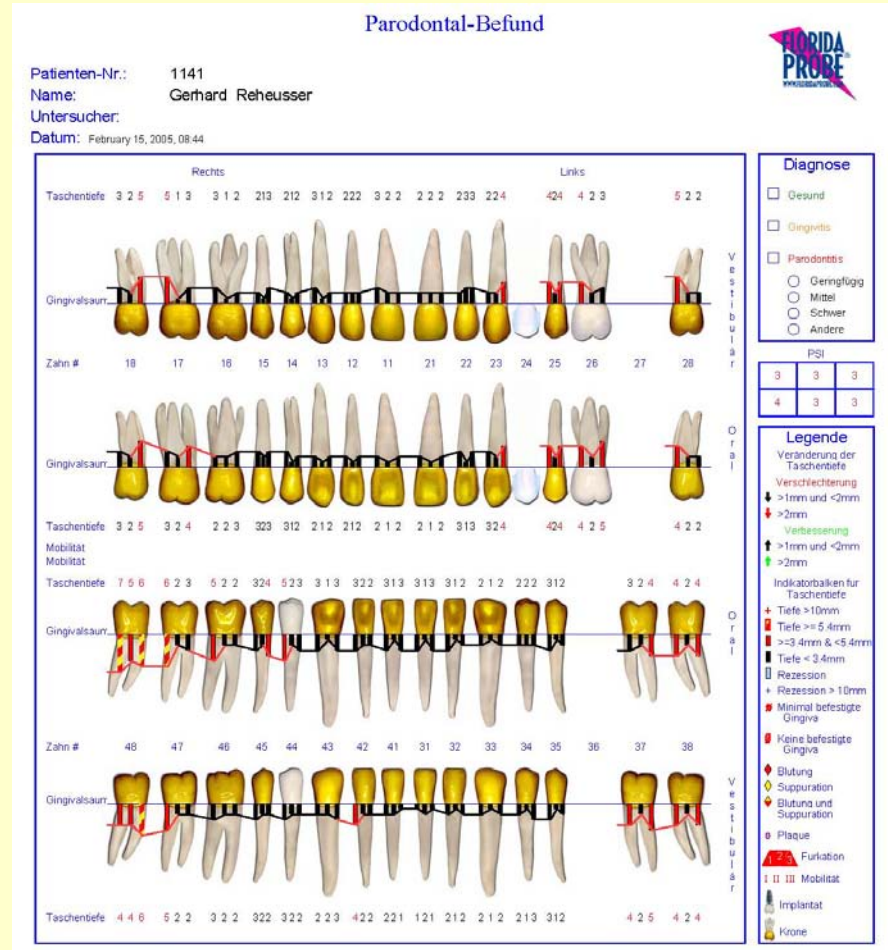


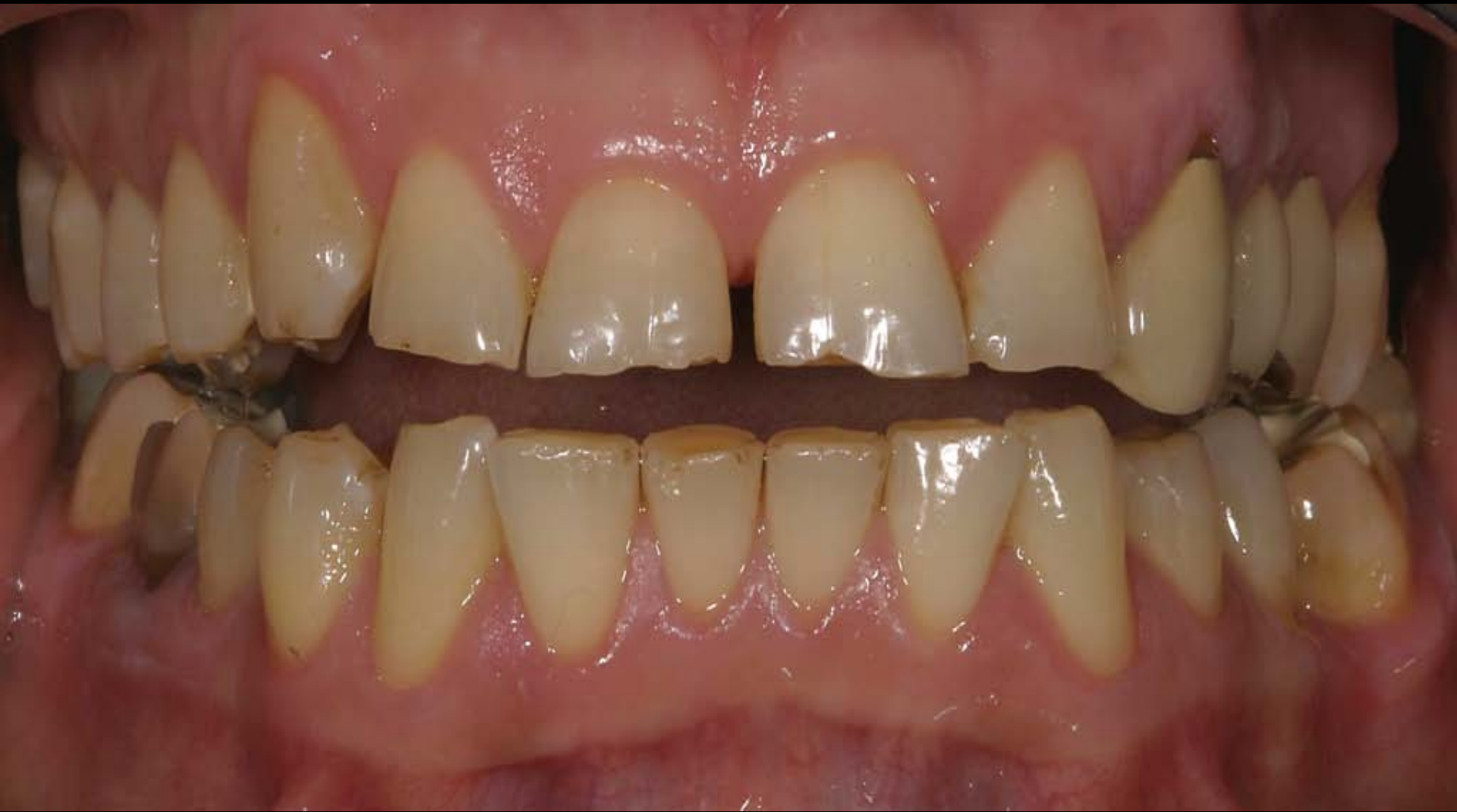## Initial presentation

Initial clinical examination

Evaluation of periodontal parameters

- Attachmentlevel
- Plaque index
- Bleeding on probing(BOP)
- Sounding on alveolar crest

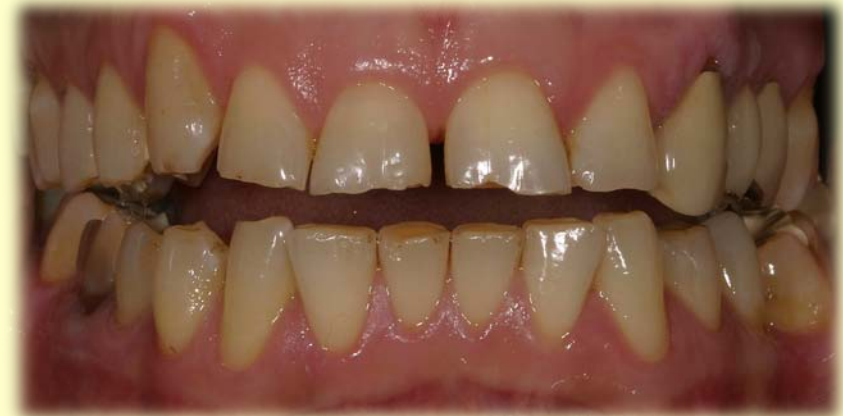



## Initial Situation

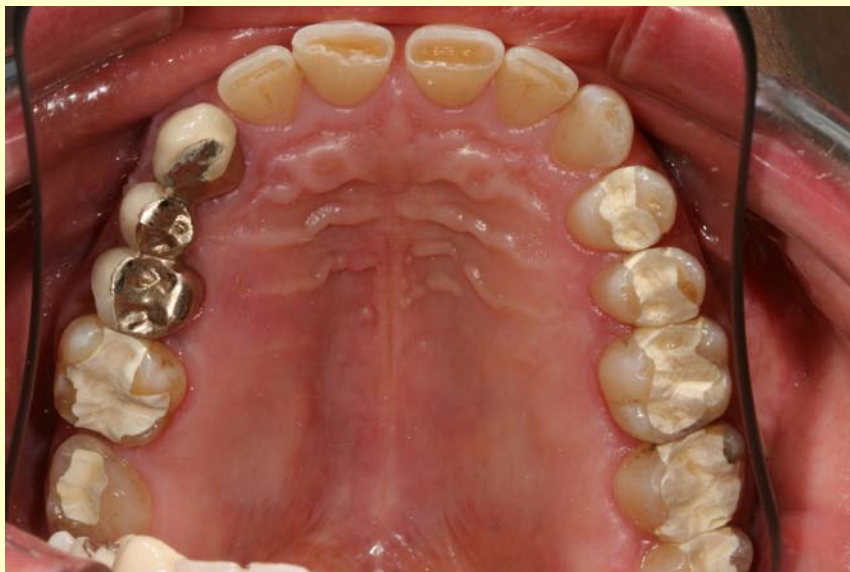### Initial clinical examination

- Generalized mild inflammation
- Generalized moderate perio
- Bleeding on probing +, pockets depths 4 to 6 in posterior region before treatment
- Parafunctional habits
- Lack of posterior support
- Moderate horizontal bone loss
- Singular recessions
- Severe occlusal and cervical abrasion
- Severe loss in VDO
- Generalized Class I mobilities
- CR  $\neq$  CO
- 0.5 mm anterior shift
- Angle Class I

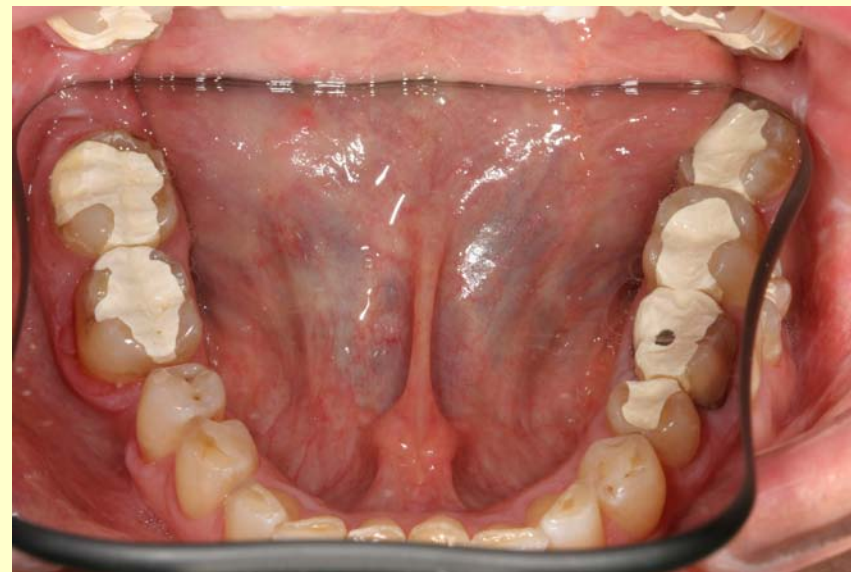




## Ausgangsbefund intraoral



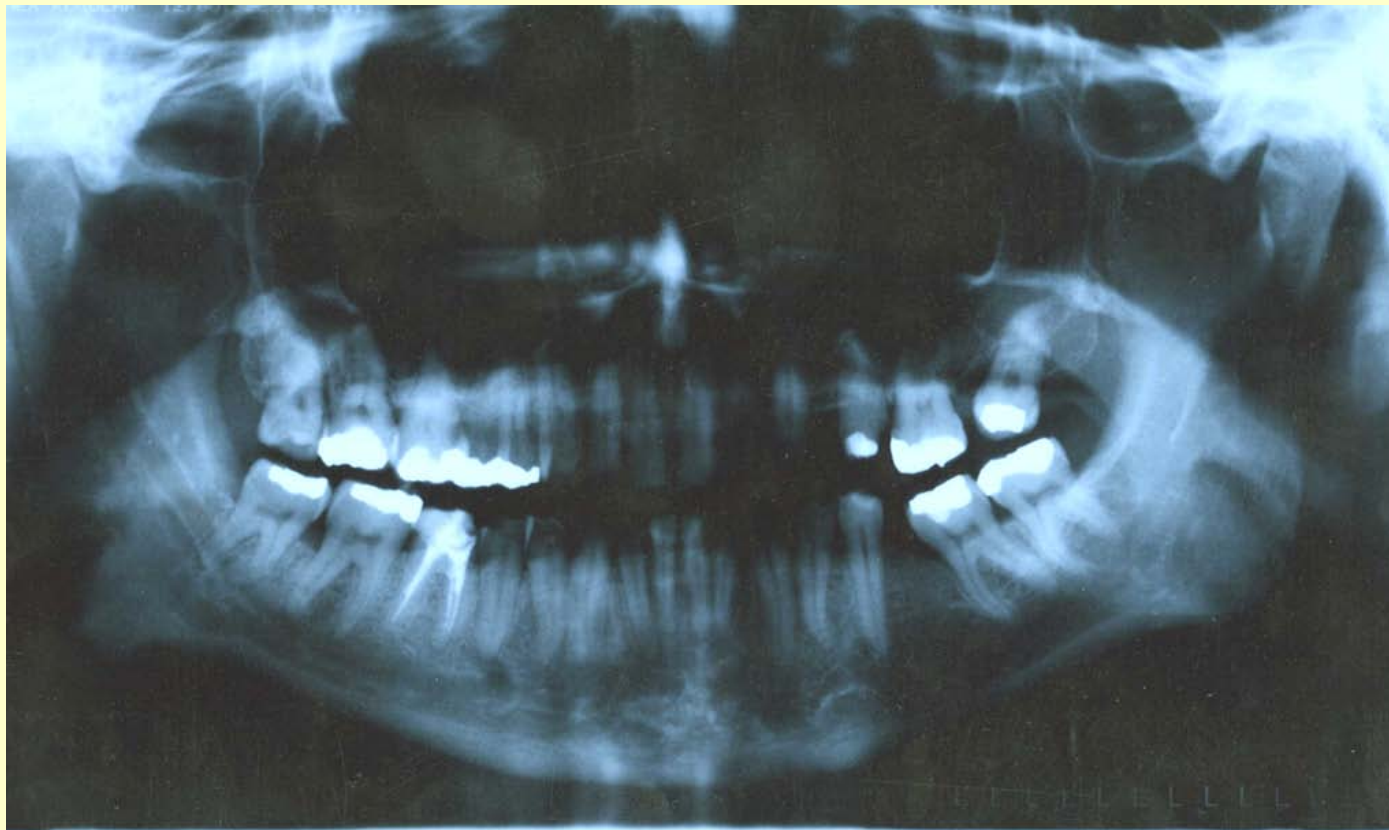Initial Situation upper jaw



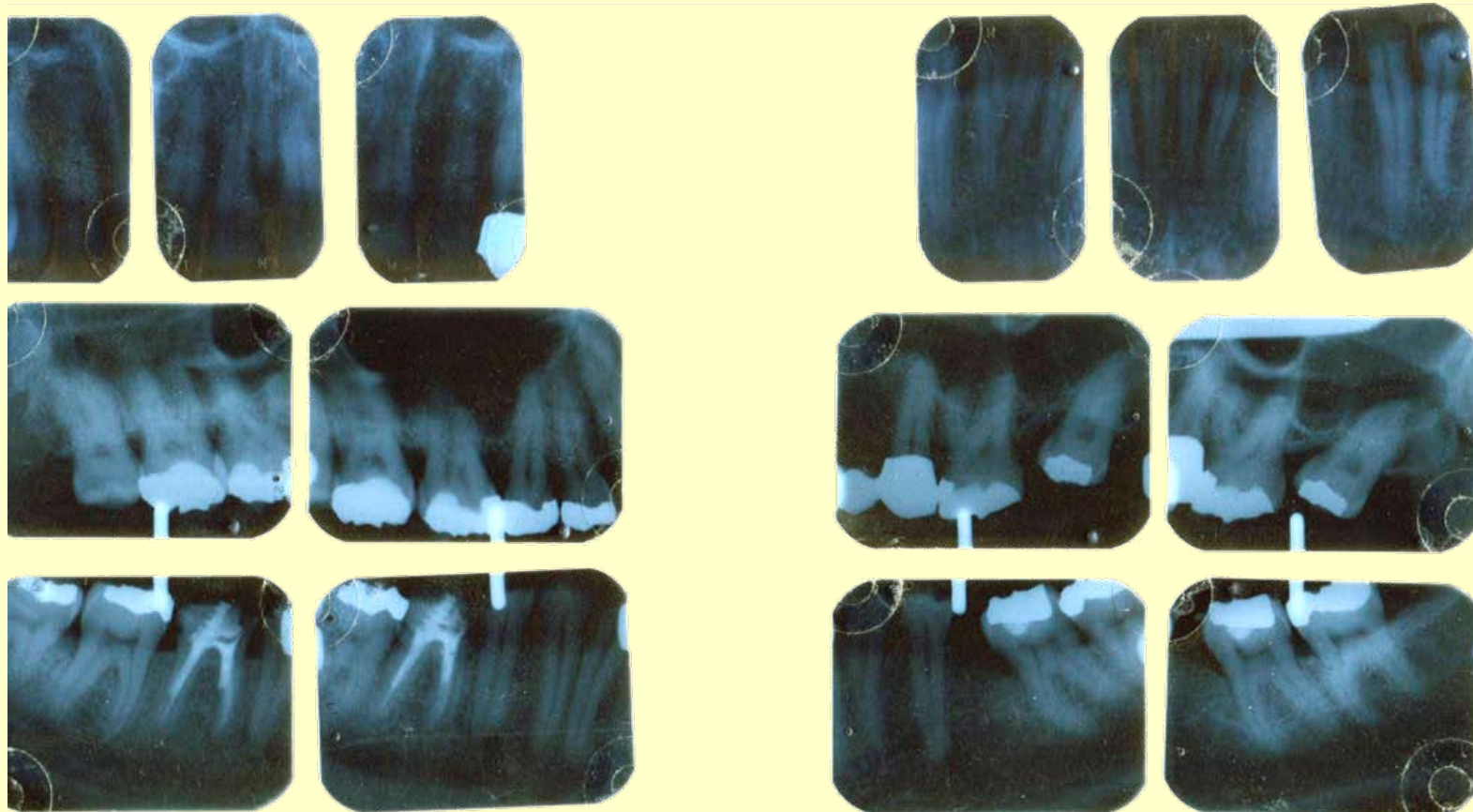
Initial situation lower jaw



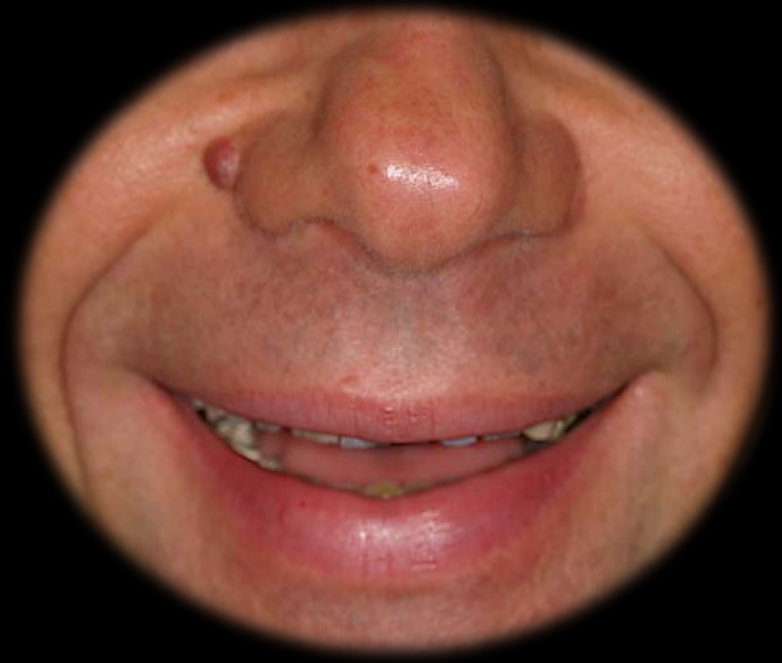## Initial X ray/ FMX/OPTG 2005



## Initial x-ray /FMX 2005

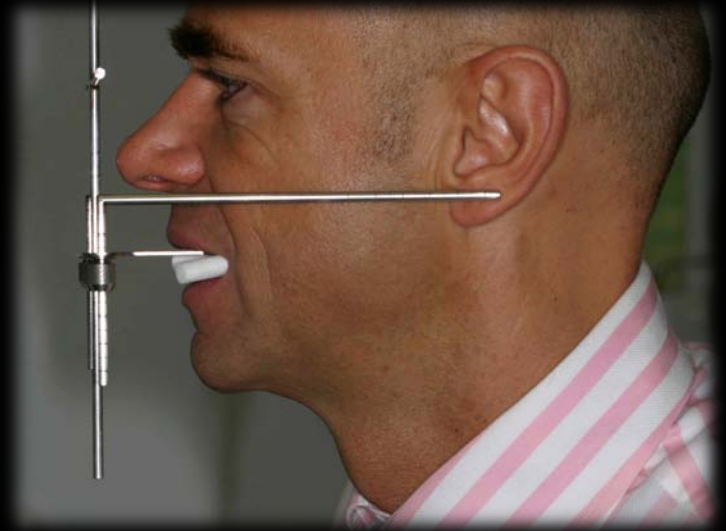




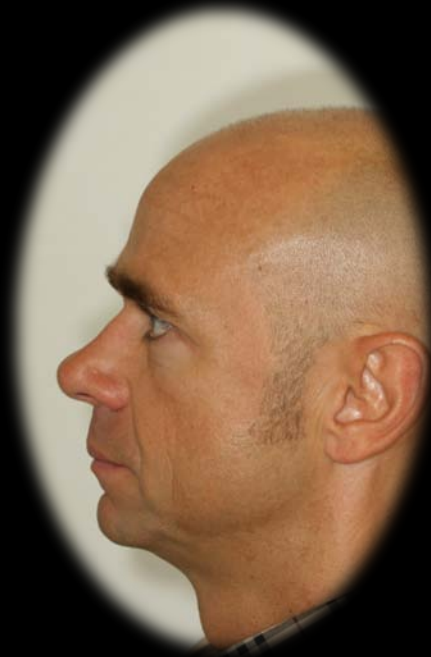
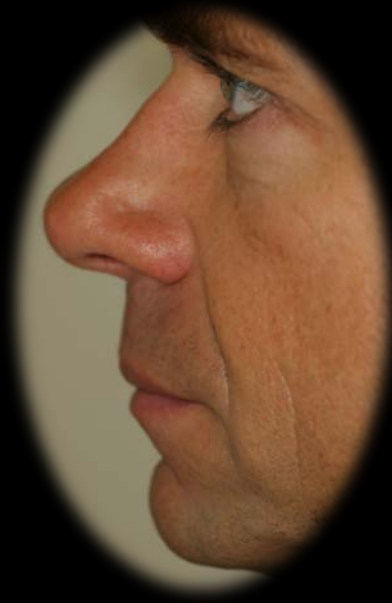

dentofacial analysis





dentofacial analysis  
Head line









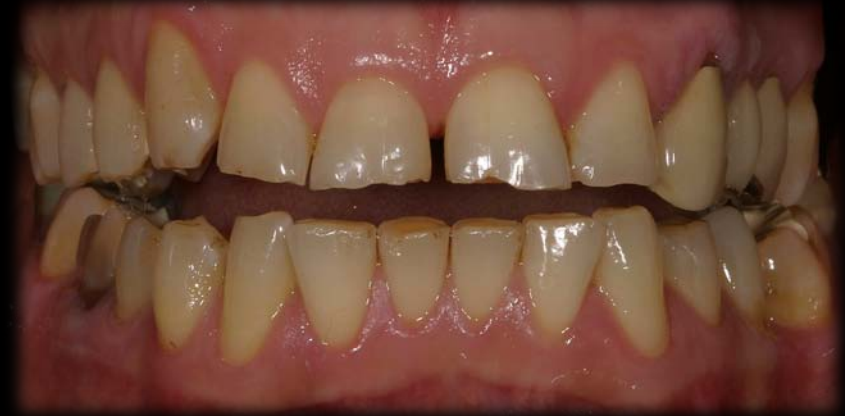




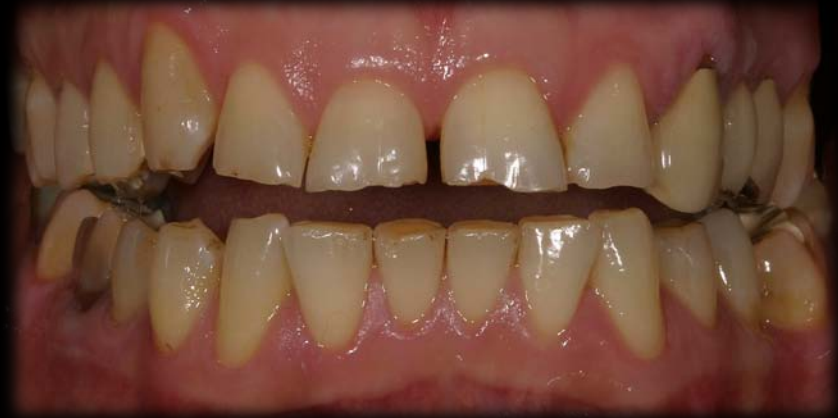


- Generalized moderate perio
- Bleeding on probing, pockets depths 4 to 6 in posterior region before treatment
- Parafunctional habits
- Lack of posterior support
- Moderate horizontal bone loss
- Singular recessions
- Severe occlusal and cervical abrasion
- Severe loss in VDO
- Generalized Class I mobilities
- CR  $\neq$  CO
- 0.5 mm anterior shift
- Angle Class I



What are your goals and objectives for this patient?





Have fun!

